

COVID 19 polyneuropathy therapy with high doses of alpha-lipoic acid - CASE REPORT

Željko Kaganović M.D.¹ Sladjana Pavic M.D. PhD², Zorica Tanasković PhD³

¹Academy of Applied Sciences Western Serbia, Uzice Department, Uzice, Serbia, e-mail: zkarganovic@gmail.com

²Department for Infectious and Tropical Diseases, General Hospital Uzice, Uzice, Serbia, e-mail: sladjanapj@gmail.com

³Academy of Applied Sciences Western Serbia, Uzice Department, Uzice, Serbia, e-mail: zoricat7@gmail.com

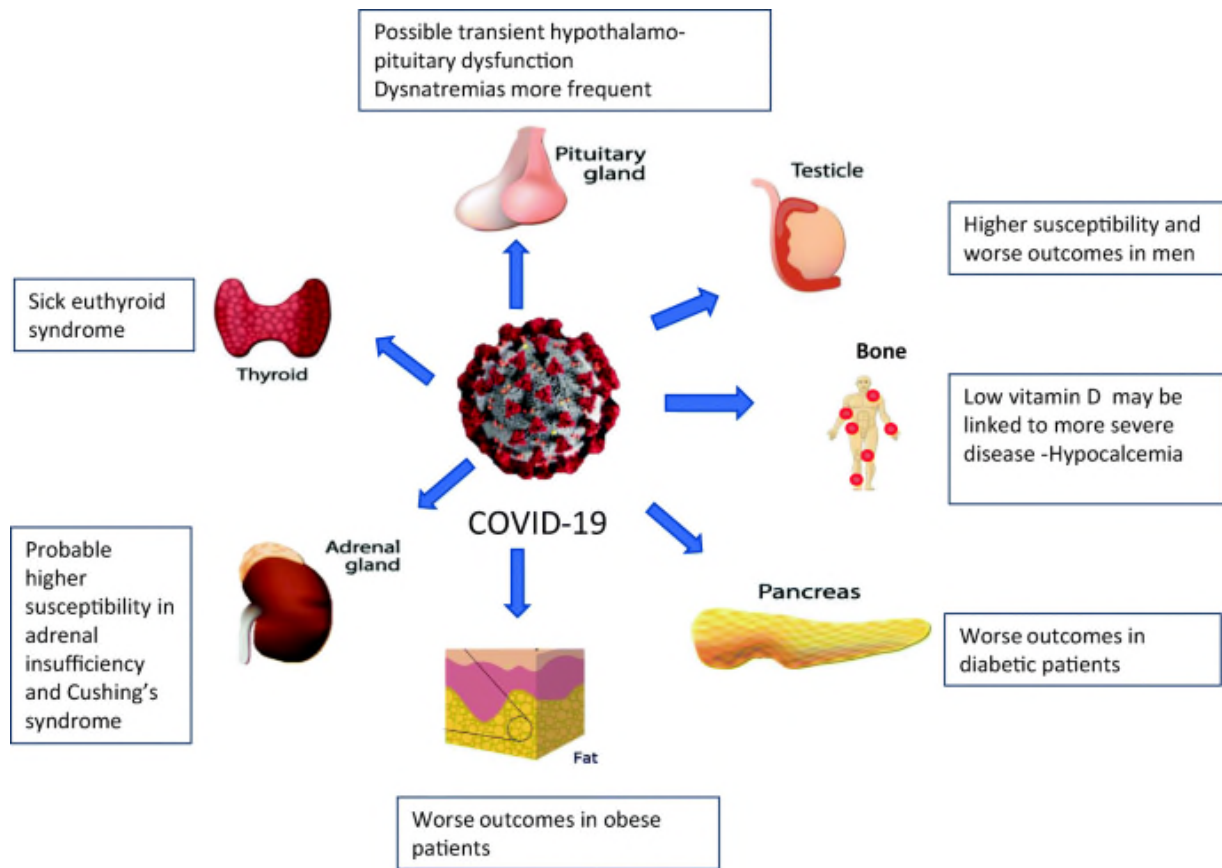
Abstract:

COVID-19 disease caused by the SARS-CoV-2 virus was first described in December 2019 in Wuhan, China, but has since spread rapidly globally. Although the number of cases and deaths has attracted a lot of media attention, less attention is paid to the long-term tribute taken by those who survived the disease. Since the discovery, there have been more and more reports linking SARS-CoV-2 infection to various nervous system disorders. These disorders can be broken down into processes that affect the brain and spinal cord that make up the central nervous system or CNS, as well as those that affect the peripheral nervous system or PNS. Every day we learn more about the spectrum of neuromuscular disorders that develop after COVID-19 disease. We present two patients with polyneuropathy after proven SARS-CoV-2 virus infection, aged 37 and 45, without previous chronic diseases that may be associated with peripheral nerve damage. The dominant symptoms in both patients are weakness and unpleasant sensations in the hands and feet, fatigue and general weakness. Therapy with high doses of alpha-lipoic acid has led to a significant reduction in discomfort and improved quality of life of patients.

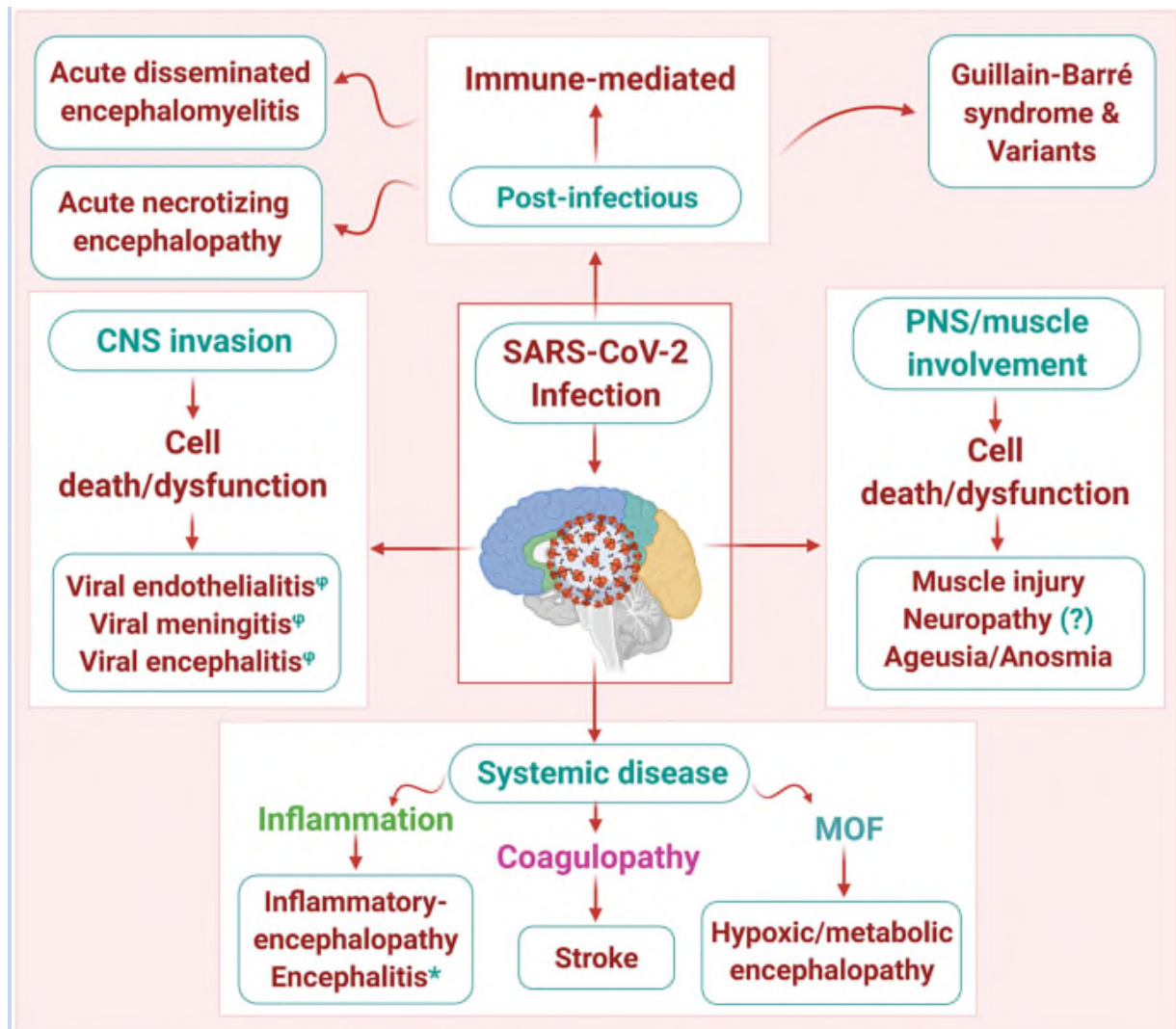
Key words: COVID-19 disease, peripheral nervous system, alpha-lipoic acid

1.INTRODUCTION

COVID-19 disease caused by the SARS-CoV-2 virus was first described in December 2019 in Wuhan, China, but has since spread rapidly globally. Although the number of cases and deaths has attracted a lot of media attention, less attention is paid to the long-term tribute taken by those who survived the disease. Since the discovery, there have been more and more reports linking SARS-CoV-2 infection to various nervous system disorders. These disorders can be broken down into processes that affect the brain and spinal cord that make up the central nervous system or CNS, as well as those that affect the peripheral nervous system or PNS (1). Every day we learn more about the spectrum of neuromuscular disorders that develop after COVID-19 disease. It will take time to fully understand the extent and extent of the residual impact in those recovering from this disease. It will take time to fully understand the extent and extent of the residual impact in those recovering from this disease. There is now growing evidence to suggest that COVID-19 may be associated with meningitis, myelitis (inflammation of the spinal cord), Guillain-Barré syndrome (a type of acute autoimmune neuropathy), and CNS vasculitis (inflammation of the blood vessels). What these disorders seem to have in common is that they are caused by an inflammatory wave to fight the infection, and not by a direct infection from the virus itself (2-3).



Neurological symptoms in patients with COVID-19



Pathophysiological mechanisms of neuronal cell damage

2. CASE REPORT

Patient A

A 37-year-old female patient developed bilateral pneumonia in November 2020 as part of a proven SARS COVID 19 infection. Soon after the cure of pneumonia, symptoms appear in the form of fatigue and tachycardia, and then the appearance of tremors, awkwardness and burning sensation, lancinating pain in the feet, weakness in the hands. Forgetfulness in terms of current events and weakness of memory, pronounced insomnia.

In the personal anamnesis: MTHFR homozygous coagulation defect, antiphospholipid sy negative, allergy to penicillin antibiotics and metamizole sodium . Laboratory analyzes are within the reference range, except for the

initially elevated D dimer. MRI of the endocranium with angiography of the brain: done due to the appearance of tremor is normal.

In the neurological finding: KN: decreased left corner of the lips, hypoesthesia of the left half of the face, Neck neat mobility, upper extremities : eutrophy, euthonia, weakened hand on both sides, MR reduced, tremor enhanced by moderate action, hypoesthesia of the left half of the body, Lower extremities: eutrophy, euthonia, weakened strength of dorsal and plantar flexors of the feet on both sides, MR reduced, Romberg sign indicated without visual control.

Patient B

A 45-year-old male patient, proven SARS COVID 19 infection in November 2020, without pneumonia. Difficulties in the form of loss of strength in the hands, more pronounced on the left, fatigue, general weakness and weakness, pain in the hands, feet and intercostal muscles.

In the personal anamnesis: without significant diseases. Pollen allergy.

In laboratory analyzes - positive Anti TPO At: 154, with signs of subclinical hypothyroidism. Cardiac Holter ECG: PSVT-introduced therapy, pericardial effusion is also detected on EHO of the heart. Occurrence of HTA that has not been registered so far.

In neurological findings: Kranial nerve: bo, Neck : neat mobility, Upper extremities: bilateral weakness of the hands, more pronounced left, MR reduced, paresthesias in the hands and forearms, Lower extremities : eutrophy, euthonia, preserved GMS, paresthesias and dysesthesias of the feet and lower legs, MR reduced, Romberg indicated without visual control.

EMNG findings in the upper and lower extremities in both patients indicate reduced values for sensitive velocities for the examined nerves of both arms, while the values of terminal latencies and motor velocities are within physiological limits.

At a standard dose of ALA (alpha-lipoic acid) of 600 mg per day, we did not get the desired results in terms of improving the discomfort. In the therapy of both patients, high doses of Alfalipoic acid of 1800 mg per day (three times more than the standard daily dose), Benfotiamine and 300 mg per day were introduced, with the addition of vitamin B complex, analgesics, Gabapentin 2x300 mg.

Only after two months from the introduction of therapy, the symptoms slowly subside, first in terms of improving muscle weakness and gradual return of muscle strength, and then significantly reduced the feeling of unpleasant sensations in terms of paresthesias and dysesthesias in the hands and feet.

3. DISCUSSION

The most common reported neurological symptom is odor loss, which can occur early in the disease process. Loss of smell, which can also affect the sense of taste, is considered temporary and most people recover their sense of smell over time. Some recent research has indicated that this is due to inflammatory changes that do not affect olfactory neurons (which receive and transmit odors from the nose to the brain), but support cells that lead to healthy nasal mucosa and healthy olfactory neurons.

Guillain-Barre syndrome is an inflammatory disorder that affects the peripheral nerves and nerve roots, which can lead to generalized muscle weakness, numbness, problems with walking, and in severe cases, affects breathing, blood pressure and the gastrointestinal system. Prior to COVID-19, Guillain-Barré syndrome was associated with an inflammatory response as a result of several infections, including *Campylobacter jejuni*, Lyme disease, EBV, HIV, and Zika virus. Almost as expected, there are now many reports of Guillain-Barré syndrome that occur during acute SARS-CoV-2 infection and during the weeks after recovery. Fortunately, if that happens, it seems that standard

treatments for Guillain-Barre syndrome will be useful, and most patients recover very well over time and with physical therapy (4-5).

What we see much more often is that many patients in our practice complain of mild but still disabling muscle weakness, fatigue and numbness or tingling after COVID-19 disease. When we see these patients, we often recommend a series of standard tests in search of neuropathy or myopathy. Checking certain blood tests is important to identify other causes of neuropathy that may contribute to these symptoms, such as vitamin deficiency or metabolic disorders such as diabetes and hypothyroidism (6).

Nerve conduction studies and electromyography (EMG) examinations can be performed to characterize the presence of neuropathy. However, making a formal diagnosis is a challenge for many patients, as nerve conduction studies and EMG are often normal relative to standard reference values from our experience. In addition, skin biopsies that look for evidence of damage or loss of small nerve endings in the skin are often also normal, although there have been no formal rigorous studies to confirm this.

Peripheral neuropathy and COVID-19 - Neuropathic pain is not an uncommon post-Covid symptom. However, we have no definitive evidence that the worsening of neuropathy symptoms is indeed due to peripheral neuropathy - or neuropathy-like symptoms arising from brain or spinal cord problems. Anecdotally, some patients with these symptoms do not show large or small fiber neuropathy on EMG and skin biopsies (7).

4. CONCLUSION

Although only a small percentage of patients with SARS-Cov-2 develop peripheral neuropathy, in a large pandemic this can have a major impact. Understanding and early detection of peripheral neuropathy associated with SARS-Cov-2 may result in improved clinical outcomes for patients and the development of improved treatment. Perhaps the most important message we share with these patients is that they know they are not alone in dealing with these symptoms. Although we may see more patients on the same day with these symptoms, we would expect people anywhere in the world to deal with these symptoms. The good news is that, although again anecdotal, we have noticed that these symptoms improve over time. As an additional note: We do not know the full range of time after post-Covid symptoms improve and it will take some time to have a more final conclusion about the full range of recovery time or to know for sure if some have permanent symptoms. However, Numerous neurological symptoms appear to improve significantly, if not fully, in many patients within a few months. The precision recovery program has not yet been agreed (8).

The aim of our work is to acquaint other fellow physicians with our experience in prescribing high doses of ALA to which there was only a therapeutic response in terms of significant reduction of neuropathic ailments in our patients. We continued the therapy for six months after the introduction, because the difficulties are still maintained, now in a very mild form.

4. REFERENCES

1. World Health Organization. Coronavirus Disease (COVID-19) Pandemic World Health Organization. 2020. Oct 30, [Last accessed on 2020 Oct 30]. Available from: <https://www.who.int/emergencies/diseases/novel-coronavirus-2019> .
2. Neurological symptoms due to Coronavirus disease 2019. Ftiha F, Shalom M, Jradeh H. *Neurol Int.* 2020;12:8639. [[PMC free article](#)] [[PubMed](#)] [[Google Scholar](#)]
3. Abdelnour L, Eltahir Abdalla M, Babiker S. COVID 19 infection presenting as motor peripheral neuropathy. *J Formos Med Assoc.* 2020; 119(6): 1119- 1120.

[Crossref](#) [CAS](#) [PubMed](#) [Web of Science](#)[®][Google Scholar](#)

4. Neuropathogenesis and neurologic manifestations of the coronaviruses in the age of coronavirus disease 2019: a review. Zubair AS, McAlpine LS, Gardin T, Farhadian S, Kuruvilla DE, Spudich S. *JAMA Neurol.* 2020;77:1018–1027.

[\[PMC free article\]](#) [\[PubMed\]](#) [\[Google Scholar\]](#)

5. A systematic review of neurological symptoms and complications of COVID-19 (Epub ahead of print) Chen X, Laurent S, Onur OA, Kleineberg NN, Fink GR, Schweitzer F, Warnke C. *J Neurol.* 2020 [\[Google Scholar\]](#)

6. Into the looking glass: post-viral syndrome post COVID-19. Perrin R, Riste L, Hann M, Walther A, Mukherjee A, Heald A. *Med Hypotheses.* 2020;144:110055. [\[PMC free article\]](#) [\[PubMed\]](#) [\[Google Scholar\]](#)

7. COVID 19 infection presenting as motor peripheral neuropathy. Abdelnour L, Eltahir Abdalla M, Babiker S. *J Formos Med Assoc.* 2020;119:1119–1120. [\[PMC free article\]](#) [\[PubMed\]](#) [\[Google Scholar\]](#)

8. Rory Abrams, M.D. and Shanna Patterson, M.D, Mount Sinai Hospital, Mount Sinai West, and Mount Sinai Morningside, Department of Neurology. Dr. Abrams and Dr. Patterson serve as Patient Education Advisors to *the Foundation for Peripheral Neuropathy*.

